

JCO INTERVIEWS

John J. Sheridan, DDS, MSD on Air-Rotor Stripping

DR. CHUDASAMA How did you develop the air-rotor stripping (ARS) system of interproximal reduction?

DR. SHERIDAN Prior to ARS, there was absolutely nothing in the literature pertaining to stripping the proximal surfaces of buccal teeth, because for decades we banded them and these surfaces were covered with metal. That changed abruptly when bonding became the standard. All proximal surfaces became approachable and, therefore, strippable during any stage of treatment. Also, traditional stripping was nearly always limited to lower incisors. That's puzzling because these teeth have the least amount of interproximal enamel and interradicular bone. Conversely, ARS is primarily, but not exclusively, targeted at reducing the thicker dimensions of buccal-section inter-

proximal enamel. It simply makes more sense.

DR. CHUDASAMA What was the initial response of the orthodontic community to ARS?

DR. SHERIDAN The initial response was cautious. The anthropological and physiological rationale was, in the main, generally accepted.^{1,2} It was the use of the handpiece that spooked clinicians. Most had not used a handpiece interproximally since dental school, and there was nothing in the orthodontic literature to give them a heads-up on how to go about it. But in due course, the commonsense appeal of ARS, amplified research, the establishment of guidelines, the endorsement of clinicians, and the contemporary appeal of non-extraction treatment has eroded this apprehension.

DR. CHUDASAMA Is treatment planning different when ARS is used?

DR. SHERIDAN Yes. I treat all ARS cases as maximum anchorage situations. The biomechanics usually involve resolution of anterior crowding and distalization of teeth into the created ARS sites. That requires anchorage-dependent space management. I don't want to remove interproximal enamel and then burn the generated space by capricious space management.

The amount of ARS to be done is usually related to the amount of crowding to be resolved (Fig. 1). There are established techniques for estimating the amount of crowding in each arch, but I've been at it so long, I choose to make my estimation primarily by clinical judgment, dividing cases into categories of mild (about 4mm) and moderate (4-8mm) crowding. If it's anything beyond 8-9mm, I'm usually reaching for the extraction pad.

I don't do all the ARS at one time, but work



Dr. Sheridan



Dr. Chudasama

Dr. Sheridan is a Professor and Dr. Chudasama is an Assistant Professor of Orthodontics, Jacksonville University School of Orthodontics, 2800 University Blvd. N., Jacksonville, FL 32211. Dr. Sheridan is also an Associate Editor of the *Journal of Clinical Orthodontics*. E-mail him at jsherid@ju.edu.

sequentially from posterior to anterior, creating one ARS site at each visit and moving the teeth, usually distally, into that space. This process, combined with in-course arch adjustments, is repeated on sequential visits until the necessary space is realized.²

And then there's the quality of the occlusion. Often there is more crowding in the lower arch, which therefore would require more interdental reduction than the upper arch. I've found that it's usually not mandatory to do preemptive stripping in an opposing arch to conform to the Bolton standard.³ Just because 6mm has been reduced in the lower arch, it does not follow that 6mm has to be removed in the upper arch. There's an acceptable range of overbite and overjet (1-3.5mm) and a range of acceptable Class I molar relationships

between the Angle standard and the more distal molar relationship of Andrews.⁴ A recent controlled study substantiated the finding that acceptable occlusal relationships can be evident throughout this range.⁵ With that in mind, I would suggest resolving the crowding with ARS and then appraising the quality of intercuspation. If it's acceptable, so be it. If it's evident that an opposing arch needs compensatory stripping for best fit, do it. But again, no preemptive strikes.

ARS is also directed at those broad, football-shaped teeth, usually first premolars, with thick proximal enamel walls. Stripping can reduce them to more efficient dimensions.

DR. CHUDASAMA How does ARS fit into the extraction-nonextraction debate?

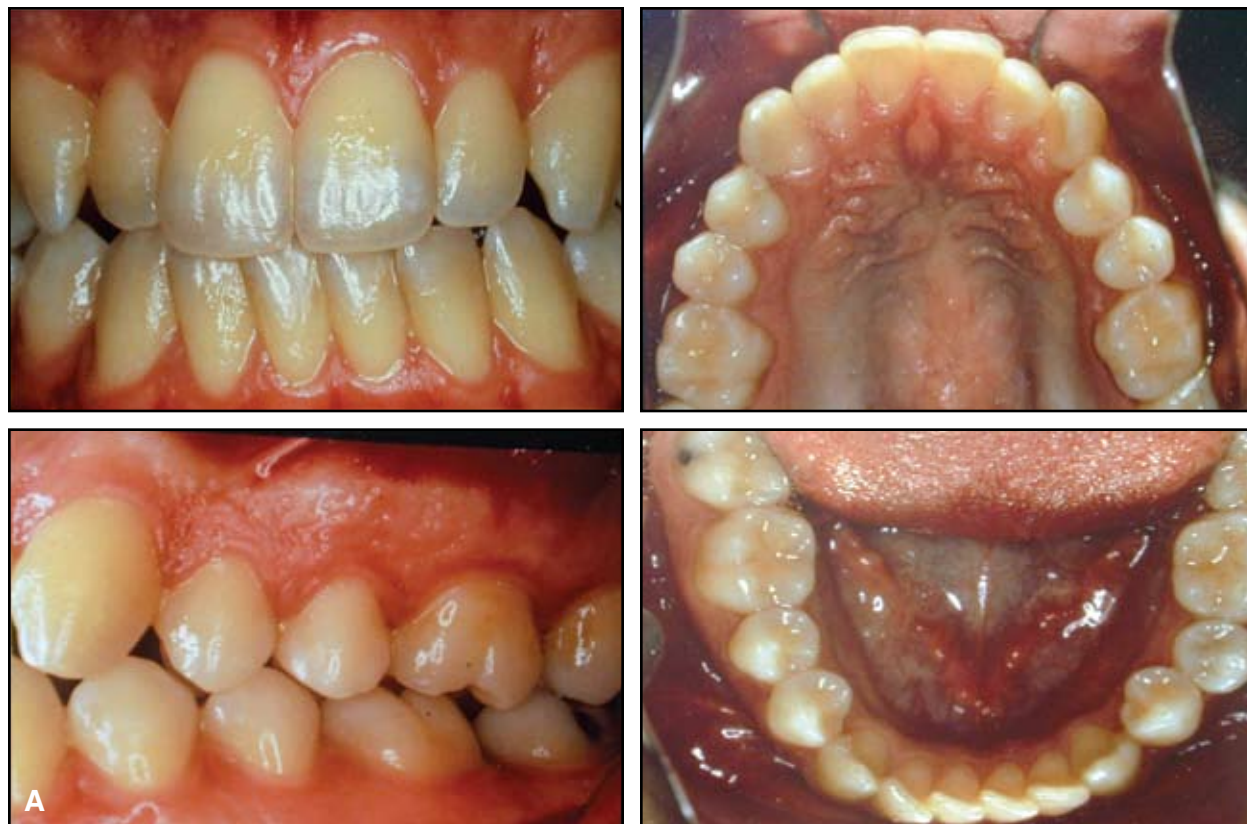

Fig. 1 A. Patient with minimal overbite and overjet, tendency toward Class III molar relationship, minimal upper crowding, and moderate lower crowding (continued on next page).

DR. SHERIDAN Not too long ago, there were only two methods to resolve mild-to-moderate crowding—extraction or expansion. Now there’s a third option, and that’s ARS that can be correlated directly to the amount of crowding. If 6mm of arch length is required, then 6mm of space can be created without any extraction space left over.

Additionally, ARS can be used in conjunction with extraction or expansion. There are situations when the extraction of teeth will not provide enough space to correct severe crowding, but extraction coupled with ARS could do the trick. Also, if expansion would excessively procline the dentition, a bit of ARS can limit flaring to a reasonable range.

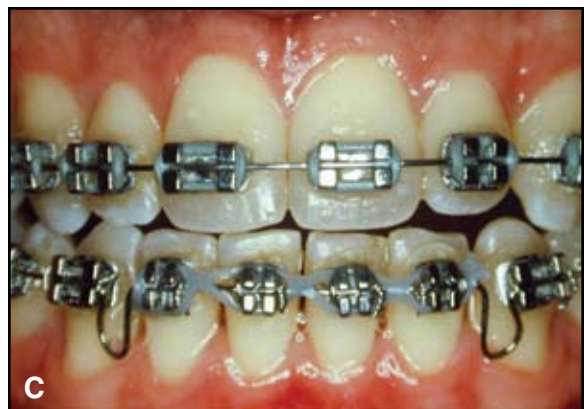
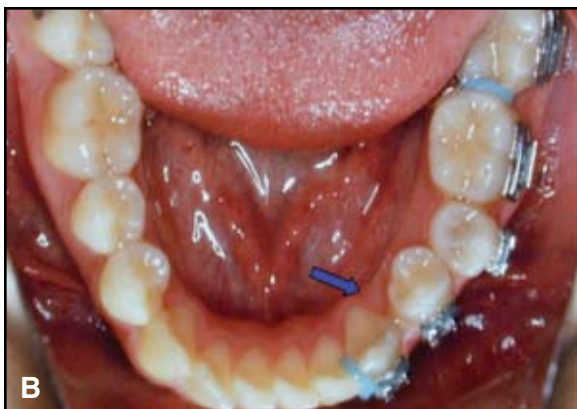
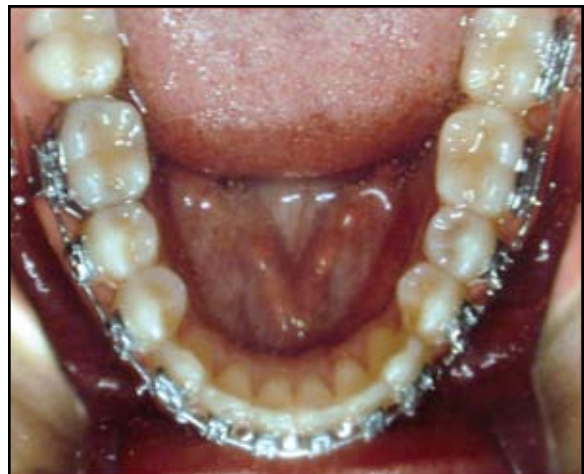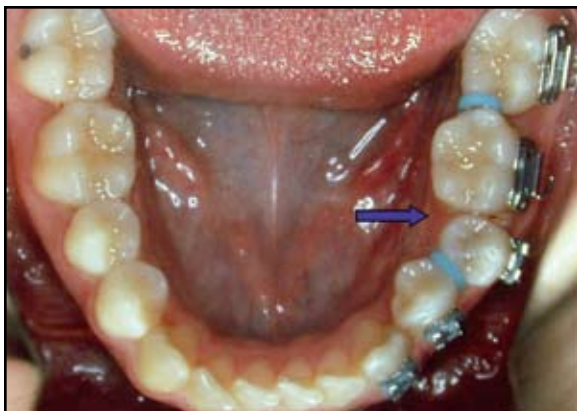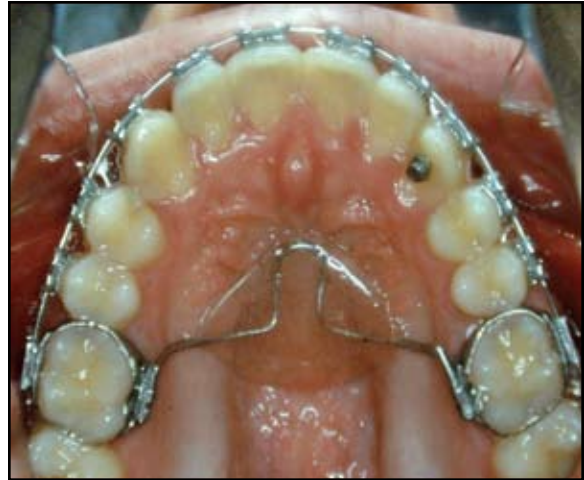Fig. 1 (cont.) B. Initial ARS sites in lower arch (arrows); separators placed to gain space for additional ARS. **C.** Appraising archform after leveling, alignment, and space management. Because lower incisors need to be retracted distally and upper incisors placed over them to establish optimum overbite and overjet, anterior ARS is also indicated (continued on next page).

DR. CHUDASAMA What are the primary guidelines for ARS?

DR. SHERIDAN The contemporary guidelines for ARS were recently published in this journal.² The most essential of these is the removal of a measured 1mm (.5mm per proximal surface) of buccal-section interproximal enamel. When stripping the lower incisors, the reduction should be limited to .75mm per contact point due to the comparatively thinner proximal enamel surfaces. You should protect the interdental tissue from laceration by the rotating bur by placing a brass wire between the contact point and the gingiva.

An air-rotor (high-speed) turbine handpiece is the most efficient instrument for the reduction and for contouring the proximals. Used with a light, wiping stroke, it is quick and precise, with minimal, if any, discomfort, and is much less laborious for the patient and the clinician than traditional hand-pulled abrasive strips, especially in the buccal sections.

Constructing an ARS site is not similar to cutting a crown prep. The contact point is not approached from the occlusal; it's approached from the proximal. The tip of the bur is placed beneath the contact point, on top of the indicator wire, and brought occlusally with a light, wiping

stroke. While doing this, the handpiece is alternated from buccal to lingual until a measured 1mm of space is apparent.

For the most acceptable contact point, I like to correct rotations, if possible, prior to initial reduction, even if it takes a bit of round-tripping. Also, the proximal walls of the reduced site should be parallel, contoured to an acceptable morphology, and finished smoothly to prevent plaque accumulation in the grooves and furrows caused by the stripping burs. Investigators have indicated that the stripped proximals can be finished to a surface that's even smoother than natural enamel.^{6,7} But still, it would be prudent to prescribe a fluoride gel or rinse to supplement the protective remineralization potential of the stripped proximal surfaces.

DR. CHUDASAMA How much space is it possible to generate within an arch?

DR. SHERIDAN It's possible to generate about 8mm of buccal space while adhering to the ARS limitation of reducing only 1mm per contact point (.5mm per proximal surface), and that's without reducing the anterior teeth. Stripping 8mm of buccal section enamel, plus what you can get from the anterior teeth, sounds a bit radical. Not so. ARS is

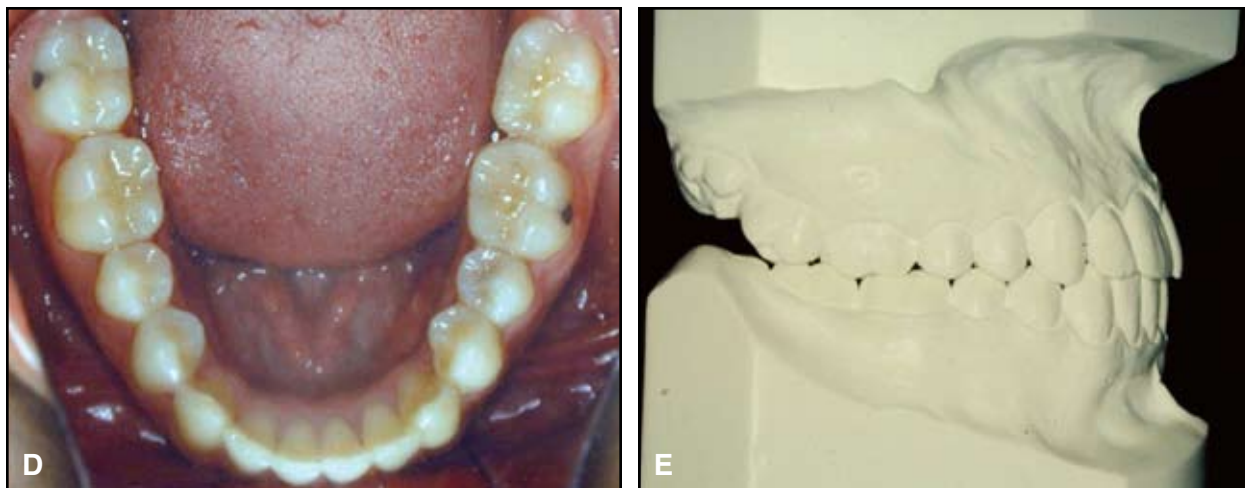


Fig. 1 (cont.) D. Lower crowding resolved without lateral or anterior expansion. E. Proper buccal intercuspation and acceptable incisal relationships after treatment.

arguably the most conservative proximal-enamel-reduction procedure described in the literature. Let me explain. The traditional guideline that pervades the literature is that it's OK to remove one-half the interproximal enamel thickness, but no one ever described how to measure this amount. It's an anecdotal guideline that was passed down from clinician to clinician. We can do better than that.

Since the enamel of a buccal-section contact point is about 3mm thick,⁸ the conventional guideline of removing one-half would result in a 1.5mm interproximal reduction. ARS is limited to 1mm per contact point—only about one-third of the enamel thickness. Not only that, but the amount of reduction can be measured to within .1mm with contemporary space gauges. With ARS, measurement can replace anecdote. That's a step up.

DR. CHUDASAMA What would you recommend for a clinician who is interested in starting to use ARS?

DR. SHERIDAN If the clinician has not used a handpiece interproximally since dental school, I would suggest that they start by working with extracted teeth mounted in stone to regain the feel of a handpiece removing interdental enamel. In this way, the parallelism of the proximal walls can be checked together with the amount of enamel that has been removed and the amount of enamel that remains. Additionally, it would be advisable to start your ARS experience with relatively minor cases—with one or two teeth out of line. As confidence is gained, the technique can be expanded to treat more complex cases.

DR. CHUDASAMA What has been your experience with patient acceptance?

DR. SHERIDAN Patient acceptance is generally positive when the benefits of the technique are discussed. These usually center on ARS being an alternative to extractions; it's not a painful procedure, and data indicate that it's not associated with dental pathology.^{9,10} Also, to ease medical apprehensions, I would recommend that an appropriate informed-consent form be presented and discussed with the patient and parents.

A format for this can be reviewed in *The Updated Air-Rotor Stripping Manual*.¹¹

DR. CHUDASAMA Some patients find the procedure uncomfortable or occasionally even painful. What can be done to lessen the physical trauma for sensitive patients?

DR. SHERIDAN ARS should be a pain-free experience, because there are no nerve endings in enamel. However, if worn burs are used, frictional heat can be generated, and that, in turn, could induce a discomforting thermal insult. Therefore, it is essential that burs be discarded when they are not reducing the enamel efficiently. Also, using water spray with ARS will dissipate generated heat, serve as a lubricant, and extend the life of the stripping bur.

But still, there are patients who, probably due to a previous traumatic dental experience, become terrified at the sound of an air-turbine handpiece winding up. If reassurance of a pain-free experience does not ease their apprehension, using hand-pulled abrasive strips would be an alternative procedure, but for the reduction of 1mm of posterior enamel, it's a very laborious one. Additionally, hand-pulled abrasive strips are not all that efficient, because you don't get as much space as you think. Forcing an abrasive strip into the contact will move the teeth into the lateral periodontal space, giving a distorted impression of the actual amount of space generated.

But there is an alternative to the rotating bur or the hand-pulled abrasive strip. The Intensiv Ortho-Strip* is a relatively new method of precisely reducing interproximal enamel. It's essentially a motorized abrasive strip that still involves the use of a handpiece, coupled with mounted abrasive strips of different configurations and reduction potentials. The handpiece has a .8mm back-and-forth shuttle action rather than the rotary action of a bur in a turbine handpiece. This system, although a bit more time-consuming, has the capability of reducing, polishing, and establishing proper contour of the enamel walls of the

*GAC International, Inc., 355 Knickerbocker Ave., Bohemia, NY, 11716; www.gacintl.com.

interproximal site.

DR. CHUDASAMA Are there any other limitations of ARS?

DR. SHERIDAN Yes. ARS cannot be relegated to an assistant—only the clinician picks up the handpiece. Also, the reduction of interdental distance limits the space available for periodontal instrumentation when disease processes are evident. The placement of separators prior to instrumentation should ameliorate this concern. Additionally, very narrow teeth limit the amount of interproximal reduction that can be performed. Finally, I would be hesitant to use ARS on a patient with obviously poor dental hygiene and hypertrophied gingiva. But then again, I would be reluctant to treat any patient who is not taking care of their teeth.

DR. CHUDASAMA How is ARS combined with Invisalign** treatment? Is there a difference in technique or tools?

DR. SHERIDAN Most Invisalign cases involve the resolution of mild-to-moderate crowding, which requires space. The concept most frequently depends on selective interproximal reduction during the progression of treatment trays. Align Technology endorses the ARS system as a means of obtaining the space—in other words, they market the ARS manual, concur with my preference of reducing burs, and are not hesitant to call for the reduction of a measured amount of buccal-section enamel to achieve a desired result. One difference is that with classic ARS, space is generated in a uniform manner from posterior to anterior on sequential appointments, while the Invisalign system will usually suggest interdental enamel removal on various target areas as the trays progress.

DR. CHUDASAMA Is ARS primarily for adults, or can it be done on children or adolescents?

**Registered trademark of Align Technology, Inc., 881 Martin Ave., Santa Clara, CA 95050; www.aligntech.com.

***Trademark of 3M Unitek, 2724 S. Peck Road, Monrovia, CA 91016; www.3Munitek.com.

DR. SHERIDAN It can be done on children and adolescents, since their interproximal enamel thickness is the same as it is in adults. However, on younger patients, the interdental soft tissue is usually more vascular and robust, totally filling the interdental space; consequently, there is the possibility of lacerating it. To avoid this, I suggest placing an Alastik*** separator in the site prior to reduction. This serves two purposes: it depresses the papilla and gets it out of harm's way of the rotating bur, and the slight separator-induced space produces better visual access for more controlled reduction. For precision, measure the separator space prior to reduction and add the recommended 1mm to it.

DR. CHUDASAMA Are there any periodontal or carious implications of the technique?

DR. SHERIDAN Not to my knowledge. For well over 50 years, proximal stripping in one form or another has been routinely discussed in the literature. Some older studies presumed that compressing the interdental bone and soft tissue, while closing the stripped spaces, would overwhelm papillae, demolish crestal bone, and cause roots to pathologically collide, but that's as far as it ever got—no in vitro verification, no observation, no controlled data. The probable cause for this hefty hole in the literature, which is obvious to those who are unhampered by perpetuated anecdote, is that the correlation between pathology and stripping does not exist. Conversely, there have been recent comprehensive literature reviews and controlled studies of the removal of interdental enamel that clearly indicate that interproximal reduction is not detrimental to dental hard or soft tissues.^{10,12,13}

DR. CHUDASAMA What happens to the enamel after ARS?

DR. SHERIDAN It is reasonable to conclude that posterior proximal stripping does not induce enamel fragility. Corroborative data indicate that interproximal mechanical abrasion potentiates a more remineralized surface that by its nature will

be more, not less, resistant to caries. El-Mangoury and colleagues concluded, "Posterior interproximal enamel reduction does not appear to expose the enamel to pathological changes that could lead to caries, but rather to a period of demineralization, followed within nine months of the stripping by remineralization."¹³ Even so, to amplify the protective remineralization effect on the stripped proximal surfaces, I would suggest putting the patient on an over-the-counter fluoride rinse.

DR. CHUDASAMA Are there any long-term studies that would suggest adverse effects?

DR. SHERIDAN I am not aware of any long-term studies indicating that ARS has any adverse physiologic or biomechanical effects. On the other hand, when ARS sites were specifically examined by various authors from one to six years after the procedure, there were no reports of an increase in the incidence of caries or periodontal distress.^{9,10,12,13}

Von der Fehr and Steinnes's statement pertaining to interdental reduction, made more than 40 years ago, is still valid and pertinent to ARS. They wrote, "Dental crowding is amenable to a corrective procedure which is too seldom undertaken, despite the simplicity and effectiveness of the procedure. A little more knowledge and the courage to offer this to the public would be of value to all concerned."¹⁴

DR. CHUDASAMA Does ARS affect retention?

DR. SHERIDAN There has been speculation that after ARS, the contact point would be somewhat flatter and therefore more resistant to rotational relapse. I don't know of any specific research that verifies this speculation, but there's a certain biomechanical logic to it, as mentioned by Paskow¹⁵ and Boese.¹⁶

Selective ARS can actually help us obtain better occlusal and incisal relationships during the finishing stages. For instance, if the buccal sections are in acceptable intercuspation, but the maxillary anterior teeth need to be retracted slightly to achieve better incisal coupling, the

distal surfaces of the maxillary laterals and cuspids can be reduced with ARS and the maxillary anterior teeth can be retracted into the space. Or if the incisors are end-on, the lower arch can be stripped for some distalization and better coupling. Therefore, if tooth widths can be modified to obtain treatment goals, it follows that the retentive potential of a better-fitting occlusion would be greater.

DR. CHUDASAMA You also pioneered the concept of retention with clear plastic devices. Where did the word "Essix" come from?

DR. SHERIDAN The word "Essix" was first used in this journal 15 years ago, when I described the fabrication and utilization of a unique plastic retainer.¹⁷ I have often been asked how I came up with the word, since it has no other known meaning. Now that I'm basking in the sunset of my career, I have garnered enough confidence to let the cat out of the bag. Stay close to me now, though, because this is a weird cat. The word "Essix" is how you would pronounce the letter S and the number 6 sequentially: "S6". Now the plot thickens. S6 is, mathematically, the letter S repeated six times. That string of six Ss stands for six words: Sheridan's Simple System of Stabilizing the Social Six. That's what "Essix" stands for. I know, I know: the moniker is more clever than traditionally descriptive, but every now and then a smile can be induced, even among orthodontists, by a bit of verbal running and jumping.

DR. CHUDASAMA Dr. Sheridan, you've been editing The Readers' Corner for JCO for 10 years. Has your outlook on orthodontics changed during that time?

DR. SHERIDAN Yes. During the last 10 years, the percentage of our adult patients has increased substantially, and clinicians are gradually establishing treatment goals to accommodate our older patients. We're getting more pragmatic—although the occlusion may not be ideal, it quite frequently has, over time, milled in and is functionally efficient. There is a tendency to leave well enough alone and concentrate on the patient's chief com-

plaint, which is usually establishing the best esthetic result possible.

Also, new graduates of our postdoctoral programs are tending to work in group practices on a substantial salaried basis rather than starting their own offices. This trend is probably centered on the heroic educational debt (usually between \$300,000 and \$450,000) that they have accumulated to pay for their undergraduate degree, dental school, and graduate training. Add to that the financial burden of starting their own practices—another few hundred thousand dollars—plus, many of these young professionals will be raising a family and financing a house. Therefore, they will be taking on a financial responsibility that could take decades to resolve. Given these realities, joining a salaried group practice, with no start-up financial burden, is an alternative to be considered.

And finally, during my years of compiling The Readers' Corner, with its focus on the pragmatic issues of clinical orthodontics, I have come to the conclusion that my colleagues are, in the main, professionals in every sense of the word. They constantly and patiently investigate the techniques and philosophies that are centered on benefit to their patients. The commonsense guidelines they eventually establish tend to be conservative. If a hot new concept or appliance is introduced, they tend to cautiously circle it until it is backed up by data and clinical reports. They are, in the main, good and decent clinicians. I'm proud to be in their company.

REFERENCES

1. Sheridan, J.: The physiologic rationale for air-rotor stripping, *J. Clin. Orthod.* 31:609-612, 1997.
2. Chudasama, D. and Sheridan, J.J.: Guidelines for contemporary air-rotor stripping, *J. Clin. Orthod.* 41:315-320, 2007.
3. Bolton, W.A.: The clinical application of a tooth-size analysis, *Am. J. Orthod.* 48:505-529, 1962.
4. Andrews, L.F.: The Straight Wire Appliance: Origin, controversy, commentary, *J. Clin. Orthod.* 10:99-114, 1976.
5. Heusdens, M.; Dermaut, L.; and Verbeeck, R.: The effect of tooth size discrepancy on occlusion, *Am. J. Orthod.* 117:184-191, 2000.
6. Piacentini, C. and Sfondrini, G.: A scanning electron microscopy comparison of enamel polishing methods after air-rotor stripping, *Am. J. Orthod.* 109:57-63, 1996.
7. Rossouw, P.E. and Tortorella, A.: Enamel reduction procedures in orthodontic treatment, *J. Can. Dent. Assoc.* 69:378-383, 2003.
8. Shillingburg, H.T. Jr. and Grace, C.S.: Thickness of enamel and dentin, *J. S. Calif. Dent. Assoc.* 41:33-36, 1961.
9. Crain, G. and Sheridan, J.J.: Susceptibility to caries and periodontal disease after posterior air-rotor stripping, *J. Clin. Orthod.* 24:84-85, 1990.
10. Pinheiro, M.L.R.: Interproximal enamel reduction, *World J. Orthod.* 3:223-232, 2002.
11. Sheridan, J.: *The Updated Air-Rotor Stripping Manual*, Raintree Essix Corp., 2002, p. 87.
12. Jarjoura, K.; Gagnon, G.; and Nieberg, L.: Caries risk after interproximal enamel reduction, *Am. J. Orthod.* 130:26-30, 2006.
13. El-Mangoury, N.H.; Moussa, M.; Mostafa, Y.A.; and Girgis, A.S.: In-vivo remineralization after air-rotor stripping, *J. Clin. Orthod.* 25:75-78, 1991.
14. Von der Fehr, F.R. and Steinnes, E.: The solubility rate of unabraded, abraded, and exposed human enamel surfaces studied by means of activation analysis, *Arch. Oral Biol.* 11:1405-1418, 1966.
15. Paskow, H.: Self-alignment following interproximal stripping, *Am. J. Orthod.* 58:240-249, 1970.
16. Boese, L.R.: Fiberotomy and reproximation without lower retention 9 years in retrospect, Part II, *Angle Orthod.* 50:168-178, 1980.
17. Sheridan, J.J.; Ledoux, W.; and McMinin, R.: Essix retainers: Fabrication and supervision for permanent retention, *J. Clin. Orthod.* 27:37-45, 1993.